

**American Board
of
Forensic Odontology**

**Diplomates Reference
Manual**

**Section IV
Standards & Guidelines**

March 2017 Edition

American Board of Forensic Odontology, Inc.

DIPLOMATES REFERENCE MANUAL

SECTION IV STANDARDS & GUIDELINES

TABLE of CONTENTS

- [DEFINITIONS of GUIDELINES, STANDARDS and POLICIES](#)
- [BITEMARK METHODOLOGY, STANDARDS AND GUIDELINES](#)
- [METHODS to DOCUMENT HUMAN BITEMARK EVIDENCE](#)
- [HUMAN BITEMARK ANALYSIS GUIDELINES](#)
- [ABFO BITEMARK TERMINOLOGY GUIDELINES](#)
- [TERMS INDICATING DEGREE of CONFIDENCE THAT an INJURY is a HUMAN BITEMARK](#)
- [TERMS USED to RELATE a QUESTIONED DENTITION to a BITEMARK](#)
- [BITEMARK CASE REVIEW GUIDELINE](#)
- [BITEMARK DECISION TREE](#)
- [ABFO GUIDELINES for INVESTIGATIVE and FINAL BITEMARK REPORTS](#)
- [ABFO BODY IDENTIFICATION INFORMATION](#)
- [BODY IDENTIFICATION GUIDELINES](#)
 - [Collection and Preservation of Postmortem Dental Evidence](#)
 - [Comparison of Antemortem and Postmortem Evidence](#)
 - [Categories and Terminology for Body Identification](#)
- [ABFO STANDARDS & GUIDELINES for DENTAL AGE ASSESSMENT](#)
 - [Purpose and Value](#)
 - [General Principles](#)
 - [Definitions](#)
 - [Standards](#)
 - [Guidelines](#)
 - [Dental Age Assessment Reports](#)
 - [Summary](#)
 - [Resources](#)

SECTION IV

Standards & Guidelines

Definitions of Guidelines, Standards and Policies

Guidelines:

- Suggested but not mandatory
- Recommended, but not required

Standards:

- A model to be followed; establishes protocol; a benchmark
- Strictly defined and to be followed by all based on its correctness
- Compulsory minimal level of practice
- More restrictive than guidelines; more enforceable

COMMENT: a failure to follow a standard may be defensible if it can be justified by proof that the standard is not worthy or that the departure is equivalent.

Policy:

- A predetermined, selected and planned prescription of conduct.
- Policies define beliefs and philosophy
- A principle, plan, or course of action as pursued by an organization

06/09

ABFO Bitemark Methodology Standards and Guidelines

Standards for Human Bitemark Analytical Methods

1. All Diplomates of the American Board of Forensic Odontology are responsible for being familiar with and utilizing appropriate analytical methods.
2. All evidence received or collected must be reviewed. The analyses performed and the results of those analyses must be included in the final report.

3. New analytical methods should be scientifically sound and verifiable. New analytical methods should be used in addition to existing accepted techniques listed in these guidelines.

ABFO Standards for "Bitemark Terminology"

1. Terms assuring unconditional identification of a perpetrator, or identification “without doubt”, are not sanctioned as a final conclusions in an open population case.
2. Terms used in a manner different from the guidelines should be explained in the body of a report or in testimony.
3. All forensic odontologists certified by the American Board of Forensic Odontology are responsible for being familiar with the standards set forth in this document.

Methods to Document Human Bitemark Evidence

Bitemark, Bite Mark, Bite-mark

The meaning of the terms is clear and there is no need for the ABFO to endorse a particular form.

1. Bite Site Evidence

General Considerations - The Forensic Odontologist is often not involved in the initial examination and collection of the bitemark evidence. This does not preclude the ability of the Forensic Odontologist to render a valid opinion. The methods listed below are not intended to be an all-encompassing list of documentation methods.

- A. Orientation photographs should be taken prior to the collection of any bitemark evidence.
- B. Saliva Swabs of Bite Site
 - Method - The double swab technique will maximize the possibility of recovering useful biological evidence from a bitemark site. The first sterile swab is moistened with sterile distilled water. Using medium pressure wash the surface of the bite site with the sterile moistened swab for 7–10 seconds. The dry sterile swab is immediately used with light pressure to collect the moisture left on the surface by the first swab. The two swabs must be air-dried at room temperature prior to submission to the laboratory, or inserted into a sterile container that allows air to circulate during storage.
 - Storage - The swabs should be submitted for analysis as soon as possible. They should be kept at room temperature if submitted within 4–6 hours, or refrigerated (not frozen) if stored longer than 6 hours.

C. Photographic Documentation of the Bite Site

- The bite site should be photographed using digital photography. The photographic procedures should be performed by the forensic odontologist or under the odontologist's direction to encourage accurate and comprehensive documentation of the bite site.
- Orientation and close-up photographs should be taken.
- Images recorded should be of high quality
- Photographs of the patterned injury should be taken with and without an ABFO #2 photometric scale in place.
- When the scale is used, it should be on the same plane as and adjacent to the patterned injury. The camera should be 90 degrees to the plane of the scale.
- In the case involving a living person or a person recently deceased, it may be beneficial to obtain serial photographs of the bitemark over time.
- Infrared, ultraviolet and alternate light photographs maybe taken when indicated in addition to conventional visible light photographs.
- Video imaging may be used *in addition* to digital photography.

D. Impressions

- Impressions should be taken of the surface of the bitemark when three-dimensional properties are present. The impression materials should meet American Dental Association specifications for intraoral use and should be identified by name in the report.
- Suitable support should be provided for the impression material to accurately reproduce body contour.

E. Tissue Samples

- In the deceased, the bite site may be excised and preserved using proper stabilization techniques prior to removal. Proper authorization should be obtained before excising any tissue.

2. Evidence Collection of Suspected Human Dentition

Prior to collecting evidence from suspected biters, the odontologist should ensure that appropriate search warrant, court order or legal consent has been obtained. A copy of these documents should be retained as part of the case record. The court document or consent should permit collection of the evidence listed below:

A. Dental Treatment Records

- Whenever possible the dental records of the suspected biters should be obtained.

B. Photography

Images acquired should include:

- Extraoral images
 - Full face
 - Profile

Intraoral photographs with retractors and mirrors:

- Anterior view in centric occlusion
 - Anterior view with incisal edges slightly opened ,
 - Anterior view with mandible protruded
 - Anterior view demonstrating maximal open with scale in place
 - Lateral views, both left and right side
 - Occlusal view of each arch
 - Additional photographs that may provide other useful information.
 - If inanimate materials are used for test bites, the results should be preserved photographically.
- Video imaging may be used to document the dentition *in addition* to digital photography.

C. Extraoral Examination

The extraoral examination should:

- Document significant soft and hard tissue features that may influence biting dynamics.
- Document temporomandibular joint function, noting any deviations in opening or closing.
- Document measurement of maximal opening of the mouth.
- Document the presence of facial scars, evidence of surgery, and the presence and nature of facial hair.
- Document facial asymmetries, muscle tone and balance.

D. Intraoral Examination:

- The periodontal condition should be noted with particular reference to mobility of teeth.
- Fractured and missing teeth should be documented.
- Any intraoral anomaly should be documented, including tori, bifid tongue, as well as tongue or lip piercings.

E. Impressions

Whenever feasible, at least two impressions should be taken of each arch, using materials that meet American Dental Association specifications and are prepared according to the manufacturer's recommendations, using accepted dental impression techniques.

- The interocclusal relationship should be recorded.
- If removable prosthetics are noted, impressions should be taken with and without the prosthesis in place.

G. Sample Bites

Sample bites should be recorded using appropriate American Dental Association materials, such as Aluwax or Coprwax.

H. Study Casts

- Master casts should be prepared and labeled using American Dental Association approved Type III stone prepared according to manufacturer's specifications, using accepted dental techniques. Other highly accurate resins may be used for model production.
- Additional casts may be poured from the original impression and labeled to indicate each additional pour if the impression material used was polyvinylsiloxane and/or polyether American Dental Association approved materials. If the original impressions were taken in alginate or other similar materials, duplicate casts may be created from an impression of the master cast. Duplicate casts should be appropriately labeled and a record of which master cast was utilized to produce the duplicate.
- Master casts should not be altered.

I. Saliva Samples

- DNA samples should be collected from all suspected biters.

Human Bitemark Analysis Guidelines

Description of Bitemark

Case data should be documented. These data should include:

1. Identification Data (case number, agency, name of examiner(s), etc.)
2. Location of Bitemark

- anatomical location or object bitten
 - surface contour: (e.g., flat, curved or irregular)
 - tissue characteristics
3. Injury features (size, shape, presence of abrasions, contusions, avulsions)
4. Other Information as indicated (e.g., three-dimensional characteristics, unusual conditions)
5. Bitemark Description
- Identification and the orientation of the maxillary and/or mandibular teeth within the bitemark
 - Identification of the midline of the maxillary and/or the mandibular teeth marks
 - Identification of marks made by specific teeth
 - Identification of areas absent of a mark(s) within a dental arch forming the bitemark
 - Identification of features within a bitemark that may indicate rotations, translations, or other anomalies of specific teeth
 - Summary of the features that comprise the nature of the injury in relationship to the teeth that caused the injury
6. Analysis of the bitemark should be completed before any comparison(s) to information from suspected biter(s) is made.

Methods of Comparing Exemplars to Human Bitemarks

1. Overlays

Types of overlays

- Computer generated
- Images of casts printed on transparency film
- Computer generated superimposition of casts over the bitemark

2. Test Bites (wax, Styrofoam, clay, skin, etc.)

3. Comparison Techniques

- Exemplars of the dentition are compared to corresponding-sized photos of the bite pattern.
- Dental casts to life-sized photographs, casts of the bite patterns, reproductions of the pattern when in inanimate objects, or resected tissue.
- All comparisons should include incorporation of the incisal height
- In cases where there is only one suspected biter, the use of a dental lineup is suggested.

- The ABFO supports a second opinion review from another Diplomate in bitemark cases

4. Other Methods Employed For Analysis

- Transillumination of tissue
- Computer enhancement and/or digitization of mark and/or teeth
- Stereomicroscopy and/or macroscopy
- Scanning Electron Microscopy
- Video superimposition
- Histology
- Dimensional

ABFO Bitemark Terminology Guidelines

Component Injuries Seen in Bitemarks

Abrasions (scrapes), contusions (bruises), lacerations (tears), ecchymosis, petechiae, avulsion, indentations (depressions), erythema (redness) and punctures may be seen in bitemarks.

A Characteristic

A *characteristic*, as applied to a bitemark, is a distinguishing feature, trait, or pattern within the mark. Characteristics are two types, *class characteristics* and *individual characteristics*.

Class characteristic: a feature, trait, or pattern that distinguishes a bitemark from other patterned injuries. For example, the finding of four approximating linear or rectangular contusions is a class characteristic of human incisors. Their dimensions vary in size depending upon what inflicted the injury: maxillary or mandibular teeth; and, whether primary or permanent teeth. Moreover, the overall size of the injury will vary depending on the contributor's arch dimension. Thus, a bitemark *class characteristic* identifies the group from which it originates: human, animal, fish, or other species.

Individual characteristic: a feature, trait, or pattern that represents an individual variation rather than an expected finding within a defined group. There are two types:

Arch characteristic: a pattern that represents tooth arrangement within a bitemark. For example, a combination of rotated teeth, buccal or lingual version, mesio-distal drifting, and horizontal alignment contribute to differentiation between individuals. The number, specificity, and accurate reproduction of these arch characteristics contribute to the overall assessment in determining the degree of confidence that a particular suspect made the bitemark (e.g., rotation, buccal or lingual version, mesial or distal drifting, horizontal alignment).

Dental characteristic is a feature or trait within a bitemark that represents an individual tooth variation. The number, specificity, and accurate reproduction of these dental characteristics in combination with the *arch characteristics* contribute to the overall assessment in determining the degree of confidence that a particular suspect made the bitemark (e.g., unusual wear pattern, notching, angulations, and fracture).

Distinctive - This term is variably defined as either rare or unusual.

- Variation from normal, unusual, infrequent.
- Not one of a kind but serves to differentiate from most others.
- Highly specific, individualized.
- Lesser degree of specificity than unique.

Bitemark Definitions

Bitemark:

- A physical alteration in a medium caused by the contact of teeth.
- A representative pattern left in an object or tissue by the dental structures of an animal or human.

Describing the Human Bitemark

A circular or oval patterned injury consisting of two opposing (facing) symmetrical, U-shaped arches separated at their bases by open spaces. Following the periphery of the arches are a series of individual abrasions, contusions, and/or lacerations reflecting the size, shape, arrangement, and distribution of the class and individual characteristics of the contacting surfaces of the human dentition.

Variations:

1. Additional features:

- Central Ecchymosis (central contusion).
- Linear Abrasions, Contusions or Striations
- Double Bite - (bite within a bite)
- Weave Patterns of interposed clothing.
- Peripheral Ecchymosis

2. Partial Bitemarks

3. Indistinct/Faded Patterned Injury (e.g., fused or closed arches, solid ring pattern)

4. Multiple Bites.

5. Avulsive Bites.

Terms Indicating Degree of Confidence That an Injury is a Human Bitemark:

A. *Human Bitemark* – human teeth created the pattern.

- *Criteria:* the pattern demonstrates class and/or individual characteristics of human teeth.

B. *Not a Human Bitemark* – human teeth did not create the pattern.

- *Criteria:* the pattern does not demonstrate class and/or individual characteristics of human teeth.

C. *Inconclusive* – there is insufficient information to reach an opinion whether or not the pattern is a bitemark.

- *Criteria:* class and/or individual characteristics of human teeth are missing, incomplete, distorted, or otherwise insufficient in the pattern.

Terms Used to Relate a Questioned Dentition to a Bitemark:

A. *Excluded as Having Made the Bitemark*

- *Criteria:* the bitemark demonstrates class and/or individual characteristics that could not have been created by the dentition in question.

B. *Not Excluded as Having Made the Bitemark*

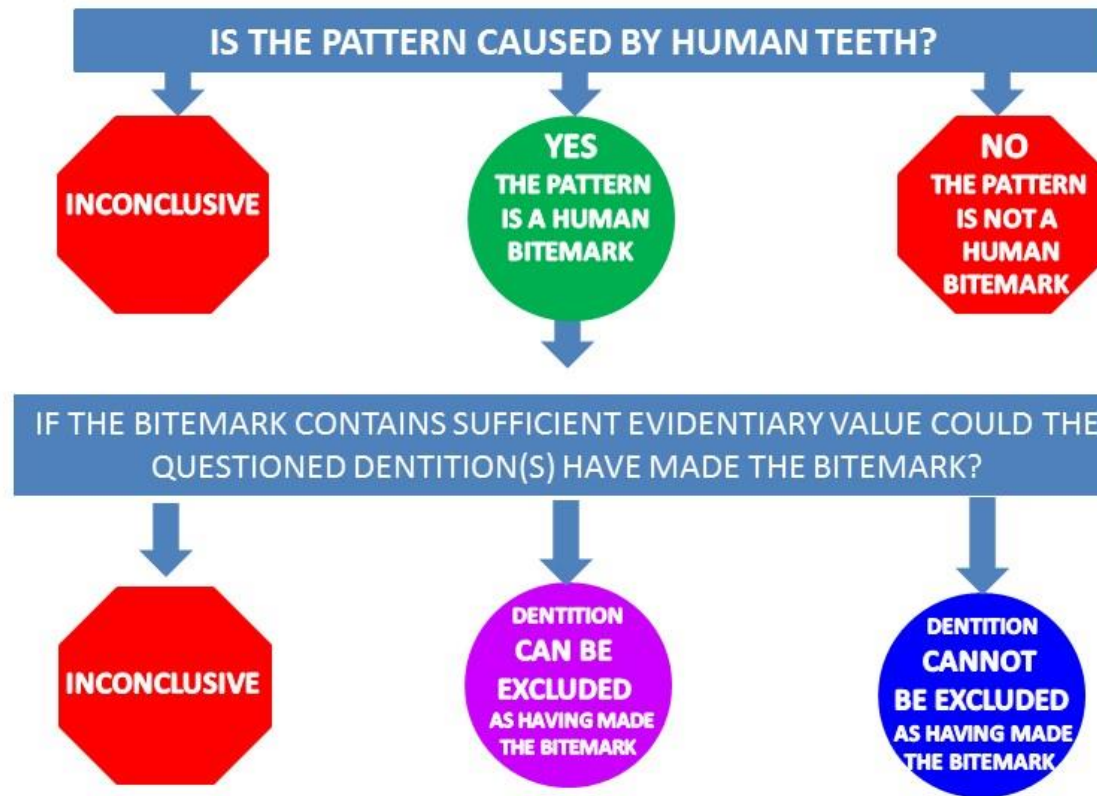
- *Criteria:* the bitemark demonstrates class and/or individual characteristics that could have been created by the dentition in question.

C. *Inconclusive*

- *Criteria:* although the analyst has concluded the pattern is a human bitemark, there is missing, incomplete, or otherwise insufficient information to form an opinion whether or not the dentition in question caused the bitemark.

ABFO Bitemark Case Review Guideline

A case review should be performed by a second ABFO Diplomat. The reviewer will not be required to provide a second opinion (but may do so if he/she wishes), but will provide an administrative review of the analysis that was done. This review should determine if the analysis and report adhered to the standards, guidelines, methodology and terminology of bitemark investigation as the required by these standards and guidelines.



ABFO Guidelines for Investigative and Final Bitemark Reports

The following ABFO Bitemark Report Writing Guidelines propose a format for written bitemark case reports. These guidelines are suggestions for the form and content of the report. Diplomates may be asked to provide preliminary or investigative reports. Those preliminary reports may follow the same general guidelines without being conclusive in nature.

Reports may be structured into the following sections:

Introduction

This section provides the background information, the “who, what, when, where and why” data related to the case.

Inventory of Evidence Received

This section lists all evidence received by the Forensic Odontologist and details the source of the evidence.

Inventory of Evidence Collected

This section lists the nature, source, and authority for evidence collected by the Forensic Odontologist.

Opinion Regarding the Nature of the Patterned Injury or Injuries

This section states the author’s opinion as to whether the patterned injuries in question are bitemarks, using ABFO terminology. Only one comparative term is used for each opinion in this part of the report.

Methods of Analysis

This section describes the analytic methods used for the patterned injuries determined to be bitemarks.

Results of Analyses

This section describes the results of the comparisons and analyses.

Opinion

This section states the author’s opinion of the relationship between one or more bitemarks and a suspected biter or biters using ABFO Bitemark Terminology. Only one comparative term is used for each opinion in this part of the report.

Disclaimer

Disclaimer statements may be included to convey that the opinion or opinions are based upon the evidence reviewed through the date of the report. The author may reserve the right to file amended reports should additional evidence become available.

ABFO BODY IDENTIFICATION INFORMATION

The importance of timely identification

In the United States, the Medical Examiner or Coroner (ME/C) has the statutory responsibility and judicial authority to identify the deceased. The identification of unidentified living individuals is the responsibility of local, state or federal law enforcement agencies. Although it is ultimately these agencies that certify the identification it is the responsibility of the forensic odontologist to provide their opinion on the identity as it relates to forensic odontology. Those opinions are based on a standardized set of guidelines established by the forensic odontology community and are based on scientific best practices.

The positive identification of an individual is of critical importance for multiple reasons that include:

For unidentified living individuals:

- A positive identification is vital to reunite an unidentified living individual with their family members.

For the human remains:

- A positive identification is vital to help family members progress through the grieving process, providing some sense of relief in knowing that their loved one has been found.
- A positive identification and subsequent death certificate is necessary in order to settle business and personal affairs. Disbursement of life insurance proceeds, estate transfer, settlement of probate, and execution of wills, remarriage of spouse and child custody issues can be delayed for years by legal proceedings if a positive identification cannot be rendered.
- Criminal investigation and potential prosecution in a homicide case may not proceed without a positive identification of the victim.

Scientific Identification

All methods of identification involve comparing antemortem data to postmortem evidence. Although a presumed identification is often established by contextual evidence, ideally, antemortem biometric data of the individual should be obtained and compared to the postmortem evidence to establish a scientific identification. Currently there are five general methods used to identify deceased human remains of which most require a presumptive identification in order to allow for the direct comparison of antemortem and postmortem biometric evidence. The five methods of identification are visual, fingerprint, DNA analysis, anthropologic/radiology and dental comparison.

Visual

A non-scientific method, but is often used when there is little doubt who the individual is, when the remains are not decomposed, and/or the death was witnessed. However changes in appearance from illness, the circumstances of death, (fire, trauma, disintegration, etc.) and postmortem taphonomic effects, (decomposition, mummification, saponification, skeletonization, animal predation/scavenging, insect activity, etc.), may render it unreliable.

Tattoos, scars, piercings, subdermal body modification, and soft tissue abnormalities are useful for visual identification, especially if the tissue is intact. It is important to note, that although personal effects were exchanged between individuals. However, they may offer important clues for a presumptive identification and assist in obtaining antemortem data on the individual to allow for a scientific are often found with the remains or at the scene (identification cards, jewelry, cell phones, etc.), they should never be used as the sole means of establishing an identification due to the possibility that these items identification.

In the future, the potential to establish a large facial image database based on facial recognition data may be possible; however, currently these databases are extremely limited in size. However, even these limited databases could be utilized to establish a presumptive identification and could assist in obtaining antemortem information in order to establish a more scientific basis of identification.

Ridgeology (Fingerprints)

Ridgeology is an expedient biometric method of human identification, especially if the soft tissue of the fingers are intact, an adequate impression or image of the friction ridges can be obtained, and antemortem fingerprint records are available. Burned, decomposed, skeletonized and fragmented remains may be more difficult, if not impossible to image, however, newer techniques have reduced this problem. This method has the advantage of large known national and international databases and does not required a presumptive identification in order to obtain antemortem information.

Anthropology/Radiology

Anthropology, combined with radiology relies on the unique characteristics of the skeleton to compare with antemortem medical imaging and records. Radiographs of skeletal anatomy, bony anomalies, healed fractures; pathological lesions, medical/surgical hardware and implants, or unusual qualities of the skeleton can be used to confirm identification. However, many individuals do not have antemortem skeletal imaging, or the images may not be available.

DNA

Like other biometric methods of identification, DNA comparison relies on access to antemortem data to make a definitive identification. However, unlike other modalities, familial relationship can be established even when antemortem data is not available. In addition, like ridgeology (fingerprints) large national databases are currently being established that can reduce the need for a presumptive identification especially if the decedent has had contact with the justice system. Direct primary and secondary reference samples from the decedent during life are the best sources for identification and indirect DNA reference samples from biological relatives can prove useful in establishing a relationship. DNA testing requires more time, effort, specialized personnel/equipment, and higher cost than other identification methods. The majority of forensic DNA tests are performed on nuclear DNA using polymerase chain reaction (PCR) amplification of the sample with short tandem repeat (STR) typing. Simultaneous analysis of mitochondrial DNA (mtDNA) may be necessary in order to improve the identification process. Forensic DNA analyses for human identification has seen a tremendous implementation since the President's DNA Initiative Program began in 2003. This program has facilitated funding, training, and assistance to ensure forensic DNA reaches its full potential to identify missing persons. From

this program, the National Institute of Justice now provides funding to have DNA analysis done on unidentified remains and family reference samples, at no cost, by the Center for Human Identification at the University of North Texas, or by the FBI. Once the analysis is complete, the profiles (if they qualify) are entered into the FBI's CODIS system (Combined DNA Index System) and uploaded into the National DNA Index System.

Dental Identification

Dental identification of a deceased person is a primary function of forensic odontology. The comparison of a missing person's antemortem dental records/evidence (i.e., written records, study casts, photographs/digital images and radiographs) with the postmortem dental evidence from unknown human remains has long been recognized as one of the most reliable means of positive scientific identification.

Though an individual's dental characteristics will often change during life (dental disease, restorations, extractions, etc.), changes after death are very slow. In fact, the dental condition at death has been shown to last in some cases for centuries.

When there is an alteration in an individual's dental condition that change is in one direction. This was described by Lorton and Langley: "The direction of change of status of a tooth is fixed; that is a tooth cannot have a filling on a surface and then proceed to a state in which there is no filling on that surface. It can only go from having no filling on a surface to a state in which there is one".

Likewise, once a tooth is extracted or otherwise missing, it cannot subsequently be present. This unidirectional change is significant during the verification process and must be considered during any comparison/search process

Forensic odontologists are responsible for identifying unknown human individuals by comparative dental analysis. This process requires comprehensive collection and processing of dental data in order to prove or disprove a human identification.

The forensic odontologist will evaluate and compare the two dental records, the postmortem and the antemortem material. It is their task to determine if the two records were made or could have been made from the same individual. Though most will employ similar techniques and routines, there can be some variation in the way that this comparison is executed. In the end however, for there to be a positive match all inconsistencies within the written records must be explained and distinguishing features must be demonstrable in the hard material evidence, i.e. radiographs, dental models, photographs, etc.

Body Identification Guidelines

OUTLINE

I. Collection and Preservation of Postmortem Dental Evidence:

- A. The Remains - Examination Procedures
- B. Photography
- C. Jaw Resection
- D. Techniques for Dissection/Resection
- E. The Postmortem Dental Record
 - 1. Dental Examination
 - 2. Narrative Description and Nomenclature
 - 3. Dental Impressions
 - 4. Dental Radiology

II. Sources for Antemortem Data:

- A. Local Agencies
- B. State Agencies
- C. Federal Agencies
- D. International Resources
- E. Insurance Carriers
- F. Other Sources

III. Comparison of Antemortem and Postmortem Evidence:

- A. Dental features useful in identification

IV. Categories and Terminology for Body Identification:

- A. Positive Identification
- B. Possible Identification
- C. Insufficient Evidence
- D. Exclusion

Some diplomates may follow alternative techniques that may be equally effective. It is not the purpose of these guidelines to invalidate other methods, but rather to describe methods that a majority of investigators employ.

I. COLLECTION AND PRESERVATION OF POSTMORTEM DENTAL EVIDENCE

The postmortem dental examination is conducted by the authority and under the direction of the coroner/medical examiner or his designee, typically a forensic pathologist. Thus, the protocol for the collection of postmortem dental evidence, particularly decisions to incise the facial tissues for access or resect the jaws, is subject to approval by the regional coroner/medical examiner. The actual procedures to be followed in a dental identification case depend in large part on the condition of the remains (as well as other circumstances of the case).

A. Examination Procedures

1. Visually identifiable body

- Photographs, radiographs, dental charting
- Dental Impressions, as applicable
- Resection by infra-mandibular dissection

2. Decomposed/incinerated body

- Photographs, radiographs, dental charting
- Resection and preservation of jaw specimens, if indicated

3. Skeletonized remains

- Photographs, radiographs, dental charting
- Preservation of jaw specimens, if indicated

B. Photography

Photographic documentation of dental evidence can provide objective data which is often more graphic than the written chart. Photographs (with an accompanying scale) should be taken before and after appropriate cleansing. The ABFO #2™ right angle ruler is recommended. The photographs should be clearly labeled with the case number/name and date. All relevant photographic information should be documented.

1. Recommended Equipment

- Single lens reflex digital or 35 mm. film based camera
- Electronic flash (preferably point flash or ring light system)
- Cheek retractors
- Intra oral front-surface mirrors

2. Film based photography

- Color film (slide and/or print format)
- Black and white film, as required

3. Photographic Views

- Full face, lips retracted
- Close-up view of anterior teeth
- Lateral views of teeth in slightly open position, and in occlusion
- Occlusal views, maxillary and mandibular teeth
- Special views, as required

C. Jaw Section/Resection

Facial dissection and/or jaw sectioning/resectioning, which may be necessary for full access to dental structures are done only with approval of the coroner/medical examiner. Ordinarily, the circumstances dictating decisions to resect are applicable as follows:

1. Viewable Bodies

Restricted opening due to rigor may require:

Intra oral incision of masticatory muscles, with or without fracture of the condyles

Breaking the rigor with bilateral leverage on the jaws in the retromolar regions

Waiting until the rigor subsides

Infra-mandibular dissection with or without mandibular resection

Removal of the larynx and tongue at autopsy may facilitate the visual examination of the teeth and/or placement of intra oral films. Again, the removal of these tissues should only be performed after the autopsy and with permission of the pathologist.

These tissues should either be retained by the pathologist or replaced with the body.

2. Decomposed, Incinerated, or Fragmented Bodies

Jaw resection in such cases facilitates dental charting and radiographic examination.

Careful dissection of the incinerated head, in particular, is required to preserve fragile tooth structure and jaws in situ. Radiographs should be made prior to manipulation of badly burned fragments. Mechanical (or chemical) sterilization of such tissue should be instituted where necessary.

3. Skeletonized Remains

Since the skull and mandible are readily separated from the remainder of the skeleton, resection of the maxilla is not required.

4. Preservation of Evidence

Jaw resection may be indicated in cases in which:

Body parts are to be transferred, with proper authorization, to other facilities for additional examination and testing.

A homicide victim is to be cremated.

There is other valid justification for preservation of the jaw specimens (state mandated law).

D. Techniques for Dissection/Resection

Selected techniques are described below. Other methods may be employed when indicated.

1. Facial Dissection:

Bilateral incisions of the face, beginning at the oral commissures and extending posteriorly to the anterior ramus, permit reflection of the soft tissues for better access.

Infra-mandibular Approach: Bilateral incisions are made across the upper anterior neck and extend to points posterior and inferior to the ears. The skin and underlying tissues are then reflected upward over the lower face thereby exposing the mandible.

2. Jaw Resection:

Stryker Autopsy Saw Method:

The soft tissue and muscle attachments on the lateral aspect of the mandible are dissected away by incisions which extend through the muco-buccal fold to the lower border of the mandible. Lingual attachments are similarly incised to include the internal pterygoid attachments to medial aspect of the rami and the masseter attachments on the lateral aspect. On the maxilla, facial attachments are incised high on the malar processes

and superior to the anterior nasal spine. Stryker saw cuts are made high on the rami to avoid possible impacted third molars. Alternatively, the mandible may also be removed by disarticulation at the temporomandibular joints. Bony cuts on the maxilla are made high on the malar processes and above the anterior nasal spine to avoid the apices of the maxillary teeth. A surgical mallet and chisel inserted in the Stryker saw cuts in the malar processes and above the anterior nasal spine are used to complete the separation of the maxilla. Remaining soft tissues in the soft palate and fauces are then dissected free.

Mallet and Chisel Method:

A mallet and chisel can be used to induce a “Le Fort” Type I fracture of the maxilla. The chisel blows are made below the zygomatic arch, high on the maxillary sinus walls bilaterally. Since it is virtually impossible to fracture the mandibular rami with the mallet and chisel, the mandible can be disarticulated at the temporomandibular joint in such cases.

Pruning Shears Method:

An alternative technique for resection of the jaws involves the use of large pruning shears. The soft tissue/muscle dissections are as described on page 10. The small blade of the pruning shears is placed within the nares and forced back into the maxillary sinus. A cut is then made along a plane superior to the apices of the maxillary teeth bilaterally. The mandibular bone cuts are performed by inserting the small blade of the shears high on the lingual aspect of the ramus near the coronoid notch bilaterally.

E. The Postmortem Dental Record:

While most morgues will have the standard autopsy equipment, the forensic odontologist may wish to assemble their own forensic kit to include mouth mirrors, explorers, camera equipment, anatomic dental charts, impression materials, cyanoacrylate, etc. Postmortem dental examinations might utilize anatomic dental charts, photographs, radiographs, models, tape recordings and/or narrative descriptions. The data collected should be comprehensive in scope since antemortem records are commonly not discovered until days, weeks or even years later. Accordingly, the post-mortem dental record will include all or most of the items given below.

1. Basic Data:

Case Number
Date/time,
jurisdiction/authority
Location
Putative ID, if any

2. Body Description, General

Approximate age
Race, sex,
condition

3. Jaw Fragment(s) Description

F. Dental Examination:

The universal tooth numbering system should be used. The record should reflect any missing dental structures or jaw fragments as well as those present and available for evaluation. The chart should illustrate as graphically as possible the following:

1. Configuration of all dental restorations (including prostheses), caries, fractures, anomalies, abrasions, implants (tooth replacement), erosions or other features for all teeth.
2. Materials used in dental restorations and prosthetic devices, when known.
3. Periodontal conditions, calculus, stain.
4. Occlusal relationships, malposed teeth; anomalous, congenitally missing and supernumerary teeth.
5. Intra oral photographs should be used to show anatomic details of teeth, restorations, periodontium, occlusion, lesions, etc.

G. Narrative Description and Nomenclature

The anatomic dental chart may be supplemented by a narrative description of the postmortem findings with particular emphasis on unusual or unique conditions. Standardized dental nomenclature should be used as follows:

1. Universal Numbering System

The system of numbering teeth that is used in the United States. The teeth are numbered from 1 to 32. The maxillary right third molar is #1, the maxillary central incisors are #8 and #9, the maxillary left third molar #16, the mandibular left third molar #17 and the mandibular right third molar is #32. The universal tooth numbering system plus the actual name of the tooth should be used (e.g. tooth #3, maxillary right first permanent molar)

2. Dentition Type and Tooth Surfaces

Primary, permanent, supernumerary, and mixed dentition. Mesial, Occlusal, Distal, Facial and Lingual surfaces (MODFL).

3. Prosthetics and other Appliances

- Crowns:** full, 3/4, 7/8, or onlay coverage restorations.
- Prosthetics:** Partial, full, or fixed dentures. Orthodontic bands, brackets, appliances, space maintainers and retainers. Mouth guards and night guards.

4. The FDI Numbering System

Odontologists should be aware of the FDI/ISO system of numbering teeth. This system is used throughout much of the world other than the United States. Quadrants are numbered from 1 to 4. The maxillary right quadrant is 1, maxillary left 2, mandibular left 3 and mandibular right 4. Teeth are numbered from the midline to the posterior. Central incisors are #1, canines #3 and third molars #8. Teeth are represented by a two digit code with the quadrant first and the tooth second. Thus, the maxillary left first molar is 26 (pronounced 2-6).

H. Dental Impressions

Impressions should be considered when bitemarks, rugae patterns or other evidence warrants the procedure.

1. Supplies and Equipment:

Appropriate trays, plastic or metal, which can be modified to fit the mouth
Alginate or other American Dental Association approved dental impression material. Type III dental stone is the material of choice for pouring models. Plaster of Paris should not be used.

2. Impressions and Preparation of Models:

Two sets of impressions, both maxillary and mandibular, are obtained in the conventional manner. Models should be trimmed and appropriately labeled with the case number and date. Also it is important to note that dental impressions on autopsy tables take longer to set.

I. Dental Radiology

Postmortem radiographs graphically complement the visual examination/charting of the oral and perioral structures and can provide significant data essential for identification (see section III). In general, radiographs are required in cases where there is no putative ID, antemortem records have not yet been located and/or the jaws cannot be retained. Postmortem radiographs must be considered the prime method of identification. A comprehensive postmortem radiographic examination might include all or some of the following views, depending on the circumstances of the case.

1. Intra oral Radiographs

Digital or analog dental bitewing and periapical radiographs of anterior and posterior teeth comparable in technique to those taken antemortem. (Bitewing views should be taken in the conventional “teeth in occlusion” manner but as an alternative periapical film can be used for separate views of the maxillary and mandibular teeth, using a horizontal bitewing angulation).

2. Dental Fragments, Dissociated Teeth

Appropriate radiographs of all dental fragments, dissociated teeth, bone and restorations should be obtained. Occlusal or lateral plate film may be used for objects larger than a periapical film.

3. Edentulous Areas

Periapical radiographs of edentulous arches or areas, especially the third molars, which may be impacted or previously extracted. Periapical radiographs of sockets of teeth lost postmortem should be taken, since antemortem radiographs of these same teeth may be the only evidence that becomes available.

4. Extra oral Radiographs

Extra oral radiographs (e.g., lateral jaw, maxillary or frontal sinus and panoramic radiographs) are often useful.

5. Disposition of Radiographs

Double pack intra oral film is recommended. One set of films should be retained by the forensic odontologist for his case file. The second set may be mounted and forwarded with a written report to the medical examiner/coroner for the master file. If digital

radiology was utilized, the odontologist should have all the digital files backed up to an external source after electronically submitting the case records.

NOTE: *All duplicate/digital films should bear right and left notations.*

II. COMPARISON OF ANTEMORTEM & POSTMORTEM EVIDENCE

This section deals with factors which may be present in both the antemortem and postmortem dental evidence and can be useful for comparison purposes. Most dental identifications are based on restorations, caries, missing teeth and/or prosthetic devices which may be readily documented in the records. It should be noted, however, that the precipitous decrease in caries incidence in recent years will dictate greater reliance on other dental findings in the future. It is emphasized that, given adequate records, a nearly infinite number of objective factors have identification value (see Section IV). Thus, objective findings, particularly those which are unique to the individual, provide the basis for concordance or exclusion. Concomitantly, apparent discrepancies between the antemortem and postmortem evidence (e.g. errors in recording, dental treatment subsequent to the available antemortem record) must be resolved. The following subsections provide examples of objective findings in the teeth, periodontium, and/or jaws, which may be demonstrable in both antemortem and postmortem records. While the factors listed are by no means comprehensive, they may serve as a checklist and demonstrate the range of objective findings that may be applicable in difficult identification cases.

Dental Features Useful in Identification:

Teeth:

Teeth present-erupted
Teeth present-unerupted/impacted

Missing Teeth:

Congenitally missing
Lost antemortem
Lost perimortem/postmortem

Tooth Type:

Permanent mixed dentition
Retained primary teeth
Supernumerary teeth

Tooth Position

Malpositions: facial/lingual version, rotations, supra/infra positions, diastemas, other occlusal discrepancies

Crown Morphology

Size and shape of crowns
Enamel thickness
Location of contact points, cemento-enamel junction
Racial variations: e.g. shovel-shaped incisors, Carabelli cusp, etc.

Crown Pathology

Caries

Attrition/abrasion/erosion

Atypical variations: e.g. peg laterals, fusion/gemination, enamel pearl, multiple cusps

Dens in dente

Dentigerous cyst

Root Morphology

Size, shape, number, dilaceration, divergence of roots

Root Pathology

Root fracture, hypercementosis, external root resorption, root hemisections

Pulp Chamber and Root Canal Morphology

Size, shape, number, secondary dentin

Pulp Chamber and Root Canal Pathology

Pulp stones, dystrophic calcification

Root canal therapy: e.g. gutta percha, silver points, endo paste, nanoparticulates, posts, and retro-fill procedures

Internal resorption, apicoectomy, periapical pathology, periapical abscess/granuloma/cyst, cementoma, condensing osteitis

Dental Restorations

Metallic restorations: amalgams, gold or non-precious metal crowns/inlays, endo-posts, pins, fixed prostheses, implants

Non-metallic restorations: acrylics, silicates, composites, glass ionomers, porcelain, zirconia, etc.

Partial and full removal prostheses

Periodontium

Gingiva: morphology/pathology

Contour: gingival recession, focal/ diffuse enlargements, interproximal craters

Color: inflammatory changes, physiologic or pathologic pigmentations

Plaque and concretions oral hygiene status, stains, calculus

Periodontal Ligament: Morphology/Pathology

Thickness

Widening (e.g. scleroderma), lateral periodontal cyst

Alveolar process and lamina dura, height/contour/density of crestal bone, thickness of inter-radicular alveolar bone exostoses, tori

Pattern of lamina dura (loss, increased density) periodontal bone loss

Trabecular bone pattern osteoporosis, radio-densities

Residual root fragments, metallic fragments

Maxilla and Mandible:

Anatomical landmarks/pathology

Maxillary sinuses: size, shape, retention cyst, antrolith, foreign bodies, oral-antral fistula

Relationship to adjacent teeth, anterior nasal spine, incisive canal, median palatal suture, incisive canal size, shape, cysts

Pterygoid hamulus: size, shape, fracture

Mandibular canal/mental foramen: diameter, anomalous (bifurcated) canal, relationship to adjacent teeth, coronoid and condylar process size and shape, temporomandibular joint size and shape, hypertrophy/ atrophy, ankylosis, fracture, arthritic changes

Other pathologic processes/jaw bones:

Developmental/fissural cysts, hemorrhagic (traumatic) bone cyst, salivary gland depression, reactive/neoplastic lesions, metabolic bone disease

Other disorders inducing focal or diffuse radiolucencies or radiopacities, evidence of orthognathic surgery or prior evidence of trauma (e.g. wire sutures, surgical pins, etc.

III. CATEGORIES & TERMINOLOGY FOR BODY IDENTIFICATION

A. Positive Identification

The antemortem and postmortem data match in sufficient detail to establish that they are from the same individual. In addition, there are no irreconcilable discrepancies.

B. Possible Identification

The antemortem and postmortem data have consistent features, but, due to the quality of either the postmortem remains or the antemortem evidence, it is not possible to positively establish dental identification.

C. Insufficient Evidence

The available information is insufficient to form the basis for a conclusion.

D. Exclusion

The antemortem and postmortem data are clearly inconsistent. However, it should be understood that identification by exclusion is a valid technique in certain circumstances.

NOTE: The forensic dentist is not ordinarily in a position to verify that the antemortem records are correct as to name, date, etc.; therefore, the report should state that the conclusions are based on records which are purported to represent a particular individual.

ABFO Standards and Guidelines for Dental Age Assessment

These standards and guidelines are the collective effort of the American Board of Forensic Odontology, Age Assessment Committee. The use of these standards and guidelines is intended to enhance the quality of forensic dental age assessment and reporting.

Use of other age assessment modalities such as anthropologic methodologies should be considered if available. All age assessment methods have advantages and shortcomings, and are dependent upon the availability or existence of suitable population specific reference data.

Purpose and Value

Forensic dental age assessment results in the estimation of an individual's chronologic age through scientific evaluation of the dentition and surrounding structures. Medico-legal applications in the deceased include estimation of the age at death to narrow search parameters and thereby assist in the identification of missing and unidentified individuals. In situations involving living individuals, dental age assessment has assisted in immigration, legal age of majority and legal age of license cases. Forensic dental age assessment practitioners should utilize the developed guidelines and standards to the fullest extent applicable, practical and appropriate to ensure scientific integrity.

General Principles

Method(s) to be employed depend upon the specific circumstances of each case. The analysis of fetal, infant, child, adolescent and adult dentitions may involve various techniques including gross examination, the use of radiographic analysis, histologic and biochemical evaluation. Forensic age assessment guidelines recommend approaches for estimating age giving consideration to the likely age range of the individual. Thoughtful consideration should be given to sex, ancestry, population specificity and environmental factors.

Definitions

Standards: Established protocols that are compulsory minimal level of practice.

Guidelines: Recommended procedures that help direct but are not required.

The use of the words “**shall**”, “**should**” and “**must**” follows the 2003 American National Standards Institute (ANSI) ,https://www.usug.org/answg/pdf/ANSI_Style_Guidesheet_-_2003.pdf, style guidelines on the correct form of requirements and recommendations:

- **Shall** is the correct verb form for indicating a requirement. Use **shall** for indicating a mandatory aspect or an aspect on which there is no option.

- **Should** is the correct verb form for indicating a recommendation where it is considered the best among numerous options or there is insufficient scientific evidence to definitively support its mandatory use.
- **Must is NOT a term recognized by ANSI and shall not be used**

Dental Age Assessment: The processes used to produce an estimation of an individual's chronologic/biologic age using dental data.

Dental Age Estimation: The mean age, age interval, and corresponding measure of the uncertainty that results from Dental Age Assessment.

Technique: A method or procedure used for age assessment.

Study: A detailed investigation and analysis of a specific population to relate chronologic age to dental development.

Rate of Uncertainty: The statistical error rate that should minimally reflect 95% of a given population or two (2) Standard Deviations (SD). If SD is not the statistical error rate utilized by a published study, then the appropriate corresponding error rate used by that study should be reported.

Prenatal/Fetal Dental Age Interval: That interval in human dental development that occurs prior to birth.

Infant/Child Dental Age Interval: That interval in human dental development that includes the postnatal presence of the developing and resorbing primary dentition including the period of mixed primary and secondary dentitions.

Adolescent Dental Age Interval: That interval in human dental development that includes the presence of the developed and developing secondary dentition. Retained primary teeth may also be present as a special circumstance during this interval.

Adult Dental Age Interval: That interval in human dental development where all teeth present have completed crown/root development and are therefore considered dentally mature.

Standards

1. The odontologist shall provide appropriate and accurate assessments of chronologic age utilizing scientific methodology.
2. The odontologist shall be familiar with currently recommended age assessment methods and shall utilize the appropriate age assessment method(s) for the case at hand.
3. The odontologist shall consider all available information, including sex, ancestry, population specificity, biological information and environmental factors.

4. The odontologist shall utilize the most appropriate statistical data to apply in the assessment of an individual's chronologic age.
5. When practical, the odontologist shall use multiple independent statistical methodologies and shall report the results of each independent statistical method utilized.
6. The odontologist shall precisely follow the specific methodology outlined, including morphologic staging and criteria measurements, within the study being utilized for the selected age assessment technique when estimating chronologic age.
7. When the technique utilized allows, the odontologist shall include a probability statement that the individual has attained the age in question for immigration and legal age of majority cases.

Guidelines

The Odontologist **Should** Record:

1. Case Identification Data:
 - a. Case number
 - b. Referring agency (Person requesting the age estimation)
 - c. Name of the examiner(s)
 - d. Date of the examination
 - e. If known, the individual's name and stated date of birth
 - f. Other pertinent informational data
2. Biographical Information of the Individual:
 - a. Ancestry and geographic population specificity
 - b. Sex
 - c. Nutritional health
 - d. Current and prior systemic diseases
 - e. Socioeconomic status
 - f. Habits and addictions that may affect health or the maxillofacial structures
 - g. Any other environmental factors that may affect morphologic or post-formation dental and skeletal development
3. Dental Evidence Observed, Collected and Measured:
 - a. Specific teeth utilized in the evaluation.
 - b. Age assessment criteria including but not limited to:
 - i. Morphologic developmental staging
 - ii. Eruption Pattern

- iii. Root translucency, Secondary dentin apposition, attrition, periodontal health, or any other measured dental developmental or post-formation characteristics.
 - c. Occlusion
 - d. Oral hygiene
 - e. Pathology
 - f. Photographs (Document Photographer and Agency Affiliation)
 - g. Radiographs (Document Radiographer and Agency Affiliation)
4. Dental Age Assessment Methods/Techniques:

Atlas

Atlas dental age assessment techniques utilize diagrammatic representations of the morphologic developing tooth structures with their associated eruption pattern. Atlas techniques are non-sex specific and have a limited number of population specific data sets resulting in a higher degree of variability particularly in mid-childhood through adolescence. In addition, Atlas techniques are often derived from mixed ethnic data. Atlas techniques are particularly useful in mass disaster and clustered victim situations due to their ability to rapidly segregate child, adolescent, and adult remains into age intervals.

Infant/Child

Infant/Child dental age assessment techniques utilize radiographic evaluation to stage the degree of morphologic development of the primary and/or secondary dentition as well as resorption of the primary dentition. Infant/Child techniques should consider sex, ancestry, and population specificity. Therefore, these techniques will generally provide a more accurate and reliable estimate of age over eruption and atlas methodologies.

Adolescent

Adolescent dental age assessment techniques utilize radiographic evaluation to stage the degree of dental development toward the latter half of dental morphologic maturation. Although, the third molar exhibits the highest degree of morphologic developmental variability, it remains extremely useful in the assessment of age. While teeth other than the third molar continue to undergo morphologic development, early adolescence age assessment methodology should be utilized. Late adolescent age assessment techniques should be utilized when the third molar is the only remaining tooth continuing to undergo morphologic development. These techniques play a useful role in assisting legal authorities in determining the disposition of cases involving immigration, asylum seekers and legal age of majority or license.

Adult

Adult dental age assessment techniques may utilize radiographic morphological evaluation as well as gross and microscopic observation of post-formation changes within the dentition following the cessation of morphologic dental development. Although others have been described, there are six traditional post-formation variables that have been utilized in the assessment of adult chronologic age. They are: root transparency, secondary dentin deposition, periodontal attachment, cementum apposition, attrition and root resorption. The most useful of the criteria are root transparency and secondary dentin deposition. The least valuable criterion is root resorption. Ethical considerations may restrict the use of many adult age assessment methodologies due to the requirement of sacrificing tooth structure.

Biochemical

Biochemical dental age assessment techniques require the sampling of dental tissues for evaluation. Current techniques include analysis of amino acid racemization and determination of the level of radioactive carbon in dental enamel. Racemization techniques estimate age at tooth extraction or death while radioactive carbon analysis estimates the date of birth for individuals born after 1943. These techniques are useful in all age groups and offer a relatively narrow age estimation interval. However, they introduce ethical considerations for tooth sampling in the living and are laboratory procedures that require considerable time and cost to process.

The Forensic Dental Age Assessment Report Should Include:

Introduction:

This section provides background information which should include;

Case Identification Data

Biographical Information regarding the individual

Inventory of Evidence:

This section lists all evidence received, observed and/or collected by the forensic odontologist and details the source of the evidence

Method(s) of Analysis:

This section describes the analytic method(s)/scientific technique(s) and population specific data used in the dental age assessment. A list of anatomic structures analyzed, specific technique(s) utilized, and the published study where statistical data was obtained should be included in the final forensic report.

Opinion/Conclusions:

This section summarizes the expert's results which should include: an overall estimate of chronologic age and an estimate of chronologic age for each technique utilized, preferably with an associated age interval at a level of 95% certainty (2 standard deviations). Additionally, when appropriate to the case, a probability statement regarding an individual's attainment of specific age.

Disclaimer:

A disclaimer statement indicating that the opinion is subject to review and/or modification if additional information or evidence becomes available.

Summary

The final age assessment results from the dental provider's expert judgment by considering all available information. Conclusion statements specific to each methodology employed should include an estimated mean age and age interval and an associated level of uncertainty. When the information is available, the level of uncertainty should statistically consider 95% of the specific population, or two standard deviations. If the peer reviewed published scientific study(s) utilized to assess chronologic age do not provide a two standard deviation statistical level of uncertainty, then, the level of uncertainty defined by that study should be clearly stated in the forensic report.

Resources:

ABFO Supplemental Age Assessment Charts: <http://abfo.org> (Located under Resources Tab)

- ABFO Dental Age Assessment Procedures Chart
- ABFO Child/Adolescent Dental Age Assessment Technique Chart
- ABFO Adult Dental Age Assessment Technique Chart

Lewis, J.M., Senn D.R., 2013. Dental age estimation. In: Senn, DR, Weems RA (Eds), Manual of Forensic Odontology, 5th Edition. Taylor and Francis Group, Boca Raton, FL, pp. 221-255.

Harris, E.F., Mincer H.H., Anderson K.M., Senn D.R. 2010. Age estimation from oral and dental structures. In: Senn, D.R., Stimpson, P.G. (Eds), Forensic Dentistry, Second edn. Taylor and Frances Group, Boca Raton, FL, pp. 263-303.

Nelson, Stanly J., and Major M. Ash. 2010. Development and eruption of the teeth. In *Wheeler's Dental Anatomy, Physiology, and Occlusion, Ninth edn.*, 21-44. St. Louis: Saunders Elsevier.

V. Gilsanz and O. Ratib 2010. Hand Bone Age: A Digital Atlas of Skeletal Maturity, Second Edition, Springer.

http://www.chospab.es/biblioteca/DOCUMENTOS/Atlas_of_Hand_Bone_Age.pdf

ABFO Dental Age Assessment Workshop (Check ABFO Website for current dates):
<http://abfo.org>

Draft Age Estimation Quicksheets™ (Assists the odontologist in calculating age, age range and rate of uncertainty using Excel Spreadsheets):
DAEQuicksheets@gmail.com

UT Age Program (Assists the odontologist in calculating age, age range and % probability of having attained a specific age. For use on Adolescents with developing third molars)
<http://logisys-consulting.com/agesetup.msi>

London Atlas of Tooth Development and Eruption 2010 Interactive Website:
<https://atlas.dentistry.qmul.ac.uk/>

Dental Age Research London Information Group (DARLInG): This assembly of pages, diagrams, numerical explanations and statistics has been written to provide a detailed and understandable explanation of the theory and practice of Dental Age Estimation. In addition, a library of Dental Age Assessment articles can be located on this web site.
<http://www.dentalage.co.uk/>

International Organization for Forensic Odonto-Stomatology (**I.O.F.O.S.**):
<http://www.iofos.eu/>